

The Role of Oxygen in Wound Healing

HBOT, TO, and TCOT
all play critical treatment roles.

BY WINDY COLE, DPM

Goals and Objectives

- 1) Understand the essential steps of the phases of the wound healing cascade
- 2) Examine the role of oxygen in controlling wound bacterial burden
- 3) Detail the importance of oxygen in growth factor regulation
- 4) Review the function of oxygen in angiogenesis and collagen formation
- 5) Introduce clinicians to the use of continuous topical oxygen therapy in wound healing

93

Welcome to Podiatry Management's CME Instructional program. Podiatry Management Magazine is approved by the Council on Podiatric Medical Education as a provider of continuing education in podiatric medicine. Podiatry Management Magazine has approved this activity for a maximum of 1.5 continuing education contact hours. This CME activity is free from commercial bias and is under the overall management of Podiatry Management Magazine.

You may enroll: 1) on a per issue basis (at \$29.00 per topic) or 2) per year, for the special rate of \$249 (you save \$41). You may submit the answer sheet, along with the other information requested, via mail, fax, or phone. You can also take this and other exams on the Internet at www.podiatrym.com/cme.

If you correctly answer seventy (70%) of the questions correctly, you will receive a certificate attesting to your earned credits. You will also receive a record of any incorrectly answered questions. If you score less than 70%, you can retake the test at no additional cost. A list of states currently honoring CPME approved credits is listed on pg. 100. Other than those entities currently accepting CPME-approved credit, Podiatry Management cannot guarantee that these CME credits will be acceptable by any state licensing agency, hospital, managed care organization or other entity. PM will, however, use its best efforts to ensure the widest acceptance of this program possible.

This instructional CME program is designed to supplement, NOT replace, existing CME seminars. The goal of this program is to advance the knowledge of practicing podiatrists. We will endeavor to publish high quality manuscripts by noted authors and researchers. If you have any questions or comments about this program, you can write or call us at: **Program Management Services, P.O. Box 490, East Islip, NY 11730, (631) 563-1604 or e-mail us at bblock@podiatrym.com.**

Following this article, an answer sheet and full set of instructions are provided (pg. 100).—Editor

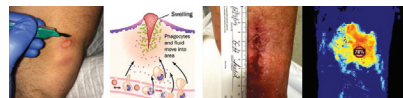
Without oxygen, there can be no life. The attainability of oxygen, the most capable electron acceptor on our planet, has allowed organisms to develop mechanisms of highly efficient energy production, which has led to the evolutionary development of aerobic life forms from the very first multicellular organisms to early vertebrates to the patients we care for today. You may recall memorizing the steps

of the Krebs cycle during your general biology studies in high school. It is through this process of aerobic respiration that most living things generate energy. In aerobic organisms, the mitochondria in cells utilize oxygen (O₂) as the final electron acceptor to synthesize high-energy adenosine triphosphate (ATP) from adenosine diphosphate (ADP) (Figure 1). ATP is the fuel needed for all human cellular processes to occur. In the absence of adequate levels of O₂, cells convert to anaerobic me-

tabolism, which is less advantageous. Hypoxia, or lack of adequate oxygen levels, will ultimately result in inadequate ATP production, tissue acidosis, and cellular dysfunction.

Understanding how wounds heal enables clinicians to apply the appropriate treatment and management techniques at each phase to support the healing process. The wound healing cascade is composed of four overlapping phases: hemostasis, inflammation, repair, and

Continued on page 94



Oxygen (from page 93)

remodeling. Although the stages of wound healing are linear, wounds can progress backward or forward depending on internal and external patient conditions. Throughout these stages wounded tissues exhibit an increased energy demand leading to a hypermetabolic state.¹ Therefore, wound healing is heavily reliant on the presence of adequate oxygen levels within the injured tissues. Oxygen is essential to multiple wound healing processes including oxidative killing of bacteria, cellular signaling and proliferation, collagen deposition, and angiogenesis.²

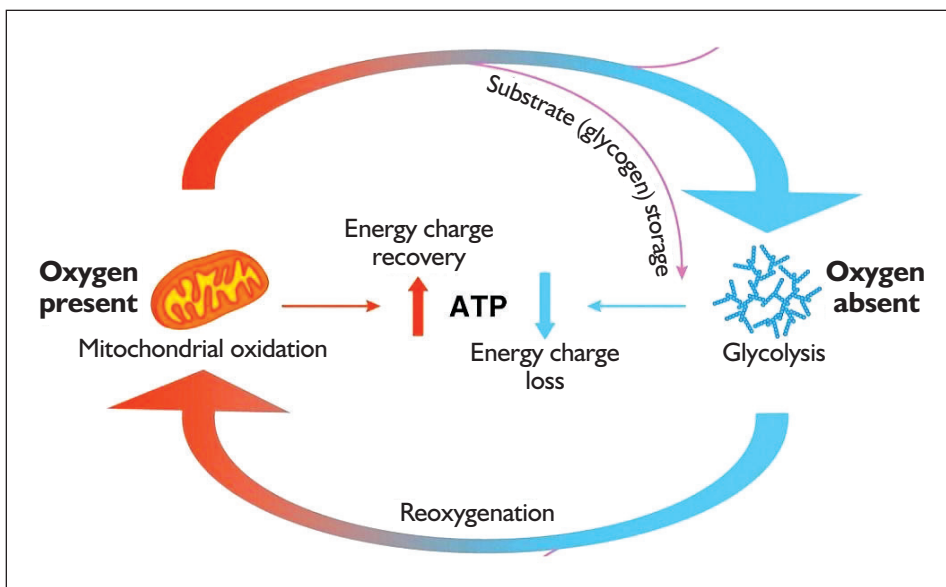


Figure 1: The synthesis of ATP from ADP via the Krebs Cycle.

The Antimicrobial Effects of Oxygen

Controlled inflammation is beneficial to wound healing. When flesh is injured (Figure 2) chemical signals

the wounded tissue.³ These phagocytic cells help to break down denatured extracellular matrix components, debris, and consume harmful bacteria.

($2O_2$). Through the process of respiratory burst, $2O_2$ is eventually converted to hypochlorous acid (HOCL). Reactive oxygen species (ROS) such as HOCL are responsible for the oxidative killing of bacteria and serve as the body's natural protection against infection.² Without adequate local tissue oxygenation, the respiratory burst is impaired, resulting in increased tissue susceptibility to infection. Certain disease conditions can also impair the formation of ROS. Chronic granulomatous disease (CGD), a primary immunodeficiency that affects phagocytes, is one such condition. CGD is caused by a mutation in NADPH oxidase.⁴

Increased oxygen levels can speed the rate of collagen deposition.

such as histamine are released triggering tissue inflammation. Local blood vessels dilate and become porous to allow phagocytic cells such as macrophages and neutrophils to migrate to

Oxygen plays a vital part in controlling bacterial burden during the inflammatory phase of wound healing. Within the membranes of neutrophils, NADPH oxidase generates superoxide

Lack of ROS formation will predispose patients to an increased risk of bacterial infection.⁴ Breathing air with reduced oxygen levels can even affect bacterial levels in wounds.

Hohn et al. conducted a study in which they determined that skin wounds of rabbits exposed to air containing low oxygen concentrations had more elevated levels of *Staphylococcus aureus* than skin

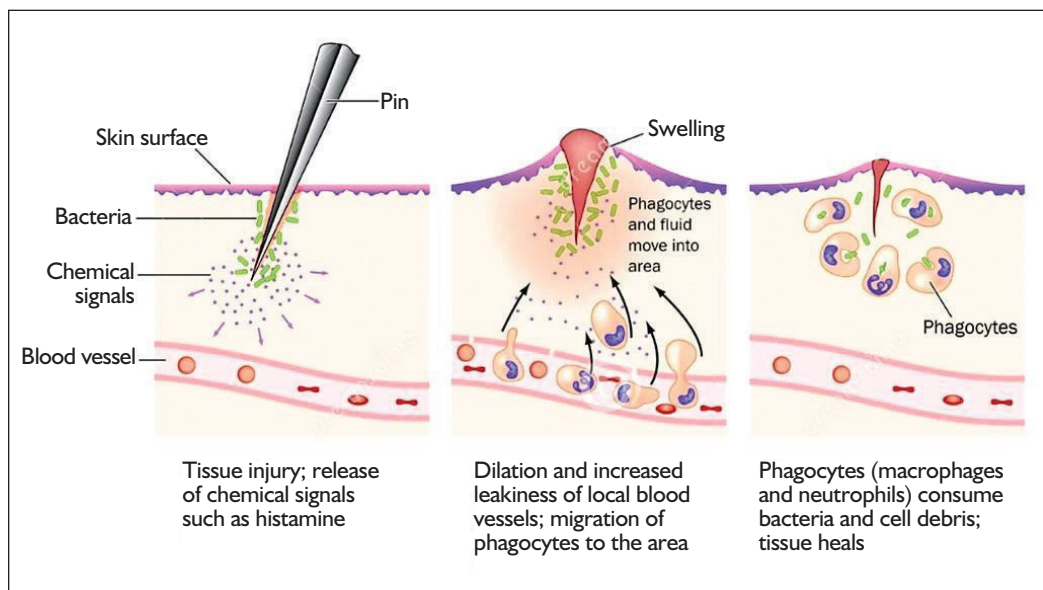


Figure 2: Tissue injury causes histamine release to trigger the inflammatory phase.

Continued on page 95

WOUND MANAGEMENT

Oxygen (from page 94)

wounds of rabbits exposed to air containing high levels of oxygen.⁵ Local tissue oxygen levels are a pivotal determinant in the overall wound microbial burden and probability of infection. Support of the body's innate immunogenic response to bacterial contamination with additional oxygen supplementation may decrease clinically significant wound infections, abscess formation, osteomyelitis, and amputations.

Growth Factor Regulation

The transition between wound healing phases is managed and regulated by biologically active substances called growth factors. These polypeptides control the growth, differentiation,

tions (20% O₂). The results of the study showed cell proliferation was three times slower with exposure to 1% oxygen versus 20% oxygen. The investigators concluded that chronically low levels of local oxygen were detrimental

The formation of the stable collagen fiber triple helix is O₂ dependent (Figure 3).⁹ Without oxygen, the hydroxylation of the proline and lysine side chains do not allow for the proper assembly of the triple helix

Angiogenesis is an important part of wound healing.

to growth factor production and led to decreases in fibroblast proliferation.⁸ Augmentation of local tissue oxygen levels may therefore enable increased fibroblast migration and proliferation in wounded tissue to help speed healing rates and prevent wound chronicity.

structure and the resulting procollagen is non-functional.^{9,10} It is these extracellular cross-linkages that are ultimately responsible for the tensile strength needed in prolonged wound healing.^{9,10}

Oxygen levels can also affect the rate of collagen deposition and possibly decrease the overall time to wound healing. Hunt and colleagues used a rabbit model to track the rate and density of collagen formation with changes in oxygen levels. The results demonstrated that exposure to hyperoxic environments accelerated collagen synthesis.⁹ Oxygen continues to be an important element throughout the remodeling stage of wound healing as continued collagen deposition during this time is key. The caliber of the collagen fibers will ultimately determine the quality of scar tissue formation. The more robust the collagen, the better the long-term healing rates of the injured tissue will be.

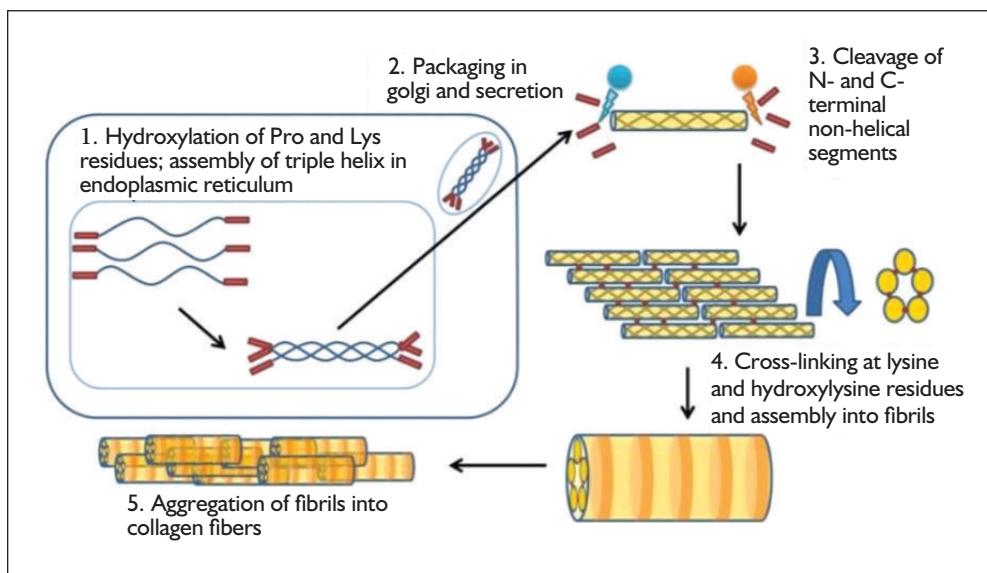


Figure 3: The formation of the stable collagen fiber triple helix.

and metabolism of cells.⁶ Fibroblasts migrate into the wound and replicate in response to growth factors released during inflammation. The essential role of fibroblasts during the reparative phase of wound healing is the secretion of the polysaccharide gel that makes up the extracellular matrix of newly formed connective tissue.⁶ ROS in low levels play a role in growth factor release. Acute hypoxia stimulates growth factor production, but chronic hypoxia inhibits or eliminates it.⁷

Siddiqui and colleagues investigated the proliferation of fibroblasts in varying environments. They compared cells grown in a hypoxic environment (1% O₂) vs. standard culture condi-

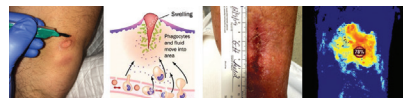
Collagen Synthesis

As the neutrophil count decreases in wounded tissue, the number of fibroblasts increases. After the extracellular matrix is laid down, fibroblasts begin to secrete collagen fibers.⁶ Collagen is the most abundant protein produced in the human body. The overall structure and integrity of human skin is proportional to the amount and quality of collagen found within the tissues. Therefore, deposition of collagen is a fundamental step in the wound healing process. The formation of this natural scaffold is essential for new tissue growth and repair. Strong collagen tendrils develop through the aggregation of mature collagen fibers with a tight triple helical structure.

Angiogenesis

The formation of new blood vessels, or angiogenesis, is another critical step in the process of tissue repair. Angiogenesis begins as growth factors stimulate endothelial cells to migrate and proliferate through a healing wound. This neovascularization begins through budding of the existing capillary network to provide new channels for active cells, nutrients, and oxygenated hemoglobin to travel to the wounded tissues (Figure 4). Vascular endothelial growth factor (VEGF) is a major angiogenic stimulus. Initially, hypoxia acts as a stimulus to

Continued on page 96



Oxygen (from page 95)

VEG-F. However, prolonged hypoxia inhibits VEG-F formation and function and obstructs neovascularization.¹¹ Supplemental oxygen wound therapy has been shown to increase VEG-F levels, thus stimulating angiogenesis. The most common forms of supplemental oxygen therapy available in the wound care space are hyperbaric oxygen therapy (HBOT) and topical oxygen therapy (TOT). The mechanism of action of these therapies varies greatly.

The effects of HBOT are based on the gas laws. Patients enter a chamber where they breath 100% O₂ while exposed to increased atmospheric pressure, typically two to three times

increase in VEG-F found within the TO group. Overall, the investigators concluded that TO showed better wound healing benefits compared to HBOT.¹¹

viewed.¹³ The group concluded that although no singular topical oxygen therapy approach is widely used universally throughout the wound heal-

Acute hypoxia stimulates growth factor production, but chronic hypoxia inhibits or eliminates it.

Increasing O₂ Levels in Wounded Tissue

From inflammation through tissue remodeling, oxygen plays a key role in the essential stages of wound healing. Despite this critical need for oxygen, levels are frequently insufficient in patients with chronic wounds due to a variety

ing community, there is a growing level of evidence suggesting its effectiveness as an adjunctive therapy to speed wound healing outcomes.¹³

It has been the author's experience that continuous topical oxygen therapy (TCOT) offers an effective non-invasive chronic wound treat-

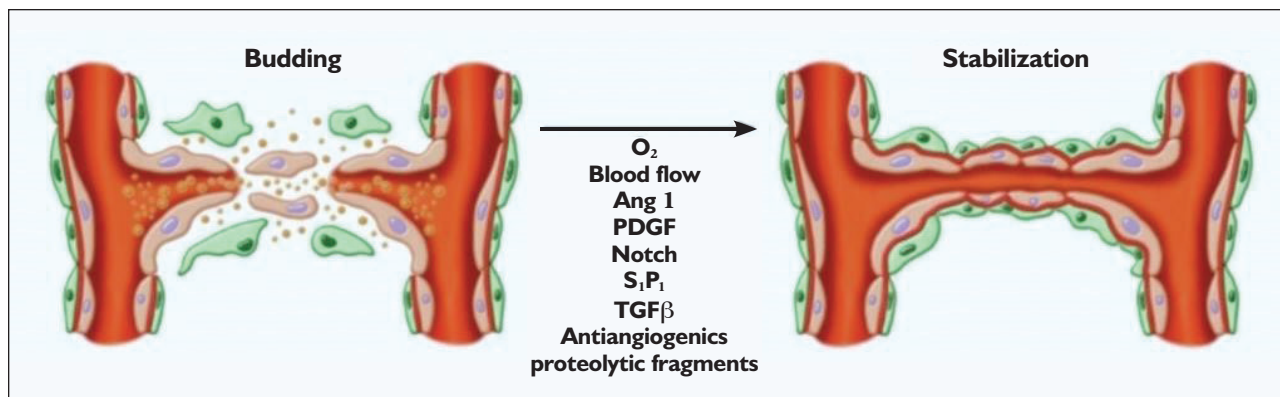


Figure 4: Neovascular budding of the capillary network.

atmospheric absolute (ATA). It is theorized that HBOT improves wound healing rates by amplifying oxygen gradients along the periphery of ischemic wounds. In contrast, TOT is a low-pressure treatment. A device delivering normospheric oxygen is directly applied to the wound. There is no increased inspiration of oxygen and the effects of TOT are localized in comparison to HBOT.

A 2008 study by Gordillo, et al. evaluated outcomes in 1,854 outpatient wound clinic patients who were screened for non-randomized enrollment into either hyperbaric oxygen therapy treatment or topical oxygen for the treatment of their chronic wounds. The investigators determined that there were no significant changes in wound measurements in the HBOT patient group. However, the TO treatment group did exhibit a noticeable decrease in overall wound dimensions. Tissue biopsies were obtained from wounds in both treatment arms. There was an

of systemic disease states causing poor circulation, inactivation of growth factors, and cellular senescence. Low levels of oxygen in the wounded tissues will prolong healing. Therefore, it stands to reason that supplying additional oxygen to wounds may promote healing.

The use of supplemental oxygen for wound healing can be traced back to the 1960s to the clinical implementation of hyperbaric oxygen (HBO).¹² Around this same time topical oxygen (TO) was also introduced for the treatment of chronic wounds. By way of research and clinical studies, HBO gained wide acceptance within the medical community as a viable adjunct to wound care therapy.¹² TO has only gained ground as a potential wound healing therapy in the last decade. Local delivery of oxygen to treat wounds has been used with varying success. In a 2015 article by Dissemmond and colleagues, evidence of the effectiveness of topical oxygen therapies for wound healing was re-

ment that may speed healing by improving microcirculation and oxygenated hemoglobin as demonstrated by the following case examples.

Case 1

An 85-year-old female presented to the wound center following trauma to her right lower leg. As our population ages, skin frailty and fragility become more than just a cosmetic concern. Decreased dermal collagen integrity in the elderly can result in friable skin that easily becomes damaged with even the most trivial of traumas. Her past medical history included insulin-dependent diabetes, chronic kidney disease, anemia, coronary artery disease, degenerative joint disease, Charcot neuroarthropathy, hypertension, hyperlipidemia, osteoporosis, and hypothyroidism, all which could impact on her ability to heal in a timely fashion.

Previous failed wound therapies

Continued on page 97

WOUND MANAGEMENT

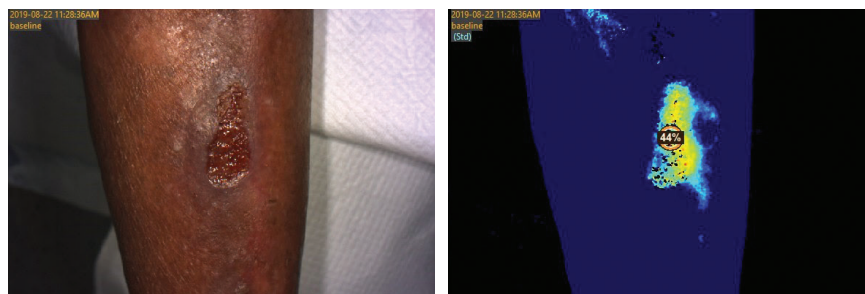

Figure 5: Case 1 baseline oxygen saturation and wound appearance.

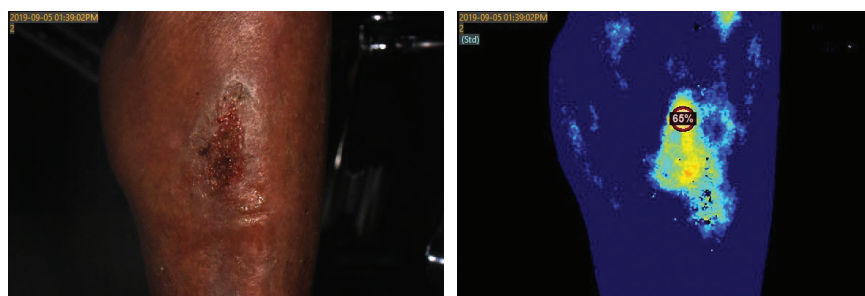


Figure 6: Case 1 3-week oxygen saturation and wound appearance.

Oxygen (from page 96)

included Santyl, alginate, and multilayer compression therapy. Non-invasive vascular testing results were within normal limits including an ABI of 1.21. Near-infrared spectroscopy imaging (NIRS) was performed in order to get a better idea of the oxygen saturation of the wound tissues. This diagnostic tool visualizes the differing optical signals based on the

evaluation. After three weeks of TO, the wound NIRS oxygenated hemoglobin level increased to 65%, and the wound dimensions had decreased by 70% (Figure 6). Based on the improvement seen in the wound and the ease of device management by the patient, it was decided to continue with TCOT therapy. By week 5 the wound was completely healed (Figure 7).

Chronic disease states commonly cause decreased circulation, inactivation of growth factors, and cellular senescence.

proportion of oxygenated hemoglobin found within the tissue capillary bed. The images obtained allow clinicians to get a better idea of the overall oxygen level present in the wound as well as assess functional blood flow to the wound and the surrounding tissues. At baseline, the wound oxygenated hemoglobin level was 44% as seen on NIRS, and wound measurements were 4.0cm x 1.5 cm x 0.1 cm (Figure 5). TCOT was initiated at this visit along with standard of care consisting of a secondary foam dressing and compression bandages. The patient was seen weekly in the clinic for standard of care and wound

In this case the wound responded incredibly well to TO therapy.

Case 2

A 76-year-old male presented to the wound center with a venous leg ulcer (VLU) on the lower inner aspect of his right leg, which had been present for 54 weeks. Past medical history included peripheral venous disease, venous insufficiency, atrial fibrillation, psoriasis, osteoporosis, degenerative joint disease, and pericarditis. Psoriasis, when coupled with venous disease, further increases the risk

of skin breakdown and complicates wound healing while elevating the likelihood of recurrence.

Previous wound management had included multilayer compression bandaging, antimicrobial creams, silver alginates, collagen, and amniotic tissue grafts. Unfortunately, the wound failed to show significant signs of healing. A full wound assessment was performed including ABI which was 1.01. Upon initial intake, the wound measured 3.1 cm x 3.2 cm x 0.1 cm (Figure 8). Significant psoriatic plaques and hemosiderin staining were evident on the patient's legs.

Near-infrared spectroscopy imaging was performed to determine the functional perfusion and oxygen saturation of the wound tissues. At baseline, the wound NIRS oxygenated hemoglobin level was 58% (Figure 9). TCOT was initiated at this visit along with standard of care consisting of a secondary foam dressing covered with a multilayer compression bandage.

Weekly wound assessments, including wound measurement, were performed in clinic. After three weeks of therapy, there were active signs of robust new granulation tissue development as well as new islands of epithelial tissue throughout the wound base (Figure 10).

At the three-week mark, the wound NIRS oxygenated hemoglobin level increased to 78% (Figure 11).

The wound continued to progress in a healing trajectory over the next few weeks with a continuous reduction in documented wound size. Complete wound closure was achieved by week 9 of therapy (Figure 12). The patient reported no issues with managing

the device in between clinic visits and was thrilled that after a year of suffering from a VLU, he had healed in nine weeks of oxygen therapy.

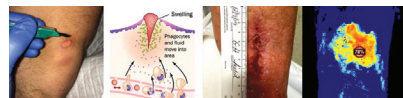
Discussion

The process of wound healing begins at the very moment of tissue injury. As detailed in this article, oxygen

Continued on page 98

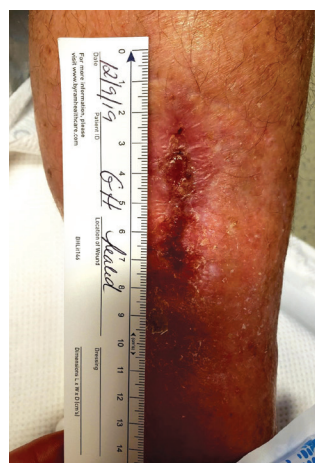

Figure 7: Case 1 By week 5 the wound was completely healed.



Oxygen (from page 97)

is essential throughout the phases of wound healing. It is an important biomarker in determining the healing potential of a wound. The oxygen gradient in wounded tissue is unequal. Supply may not meet demand. This is especially true in patients suffering from systemic conditions such as diabetes and venous disease. Although the etiology of non-healing chronic wounds is multi-factorial, hypoxia is a common component in a vast majority of cases.

Healing wounds characteristically have a limited inflammatory phase, high cellular mitogenic activity, robust neovascularization, intact functional extracellular matrix, strong new collagen deposition, and increased tissue tensile strength; whereas chronic wounds display a prolonged inflammatory phase, low mitogenic activity, a dysfunctional matrix, senescent cells, and excessive scarring and contracture. Oxygen levels in the tissue are a major contributory factor in determining the wound's clinical pathway. Hypoxia is a common limitation to healing in chronic wounds of varying etiologies. Maintaining adequate levels of oxygen in wounded tissues continues to be a challenge.

For many years, hyperbaric oxygen therapy (HBOT) has been employed to deliver high-pressure 100% oxygen to the tissue in the hopes of increasing wound oxygenation. HBOT relies on adequate arterial perfusion in order to transfer oxygen to the wounded tissue. The advent of newer technologies can now enable small, portable battery-powered oxygen generators to allow continuous oxygen therapy (TCOT) to be applied directly to the wound base at normospheric pressure. TCOT is a novel treatment that may potentially be applied to a broader cross-section of patients to improve long-term wound healing outcomes. Each of these modalities has both pros and cons. It is imperative that clinicians choose the appropriate treatment course based on the needs of the patient. Most commonly, successful wound healing occurs as a culmination of multiple evidence-based therapeutic modalities

working in conjunction with each other.

It has been the author's experience that utilizing NIRS to monitor and track tissue oxygenation has proven to be an effective predictor of wound healing. By incorporating this near-infrared imaging technology, the limitations typically found with standard NIVS have been eliminated. In the patient cases presented in this manuscript, the NIRS was able to track changes in the oxygen levels of wound tissues with more precision than ABI alone. The changes noted

in wound tissue oxygenation exhibited in these case studies also had better correlation with the weekly clinical appearance of the wound. Using treatments that maintain oxygen levels can decrease median time to heal in chronic recalcitrant wounds of multiple etiologies. Using non-invasive devices such as NIRS to track wound oxygen levels will help clinicians determine the appropriate therapeutic pathway for each individual patient week to week.

Oxygen is vital throughout the wound healing process, especially in the inflammatory and proliferative phases. Research suggests that patient supplementation with oxygen could enhance bacterial killing, increase growth factors, expedite collagen deposition, and improve angiogenesis. Long-term studies are needed to determine if supplemental oxygen therapy can also reduce surgical site infection rates and increase wound tensile strength. The importance of oxygen is often overlooked. Adequate supply does not just come from the air we breathe. Many different supplemental oxygen therapeutic modalities are

Continued on page 99

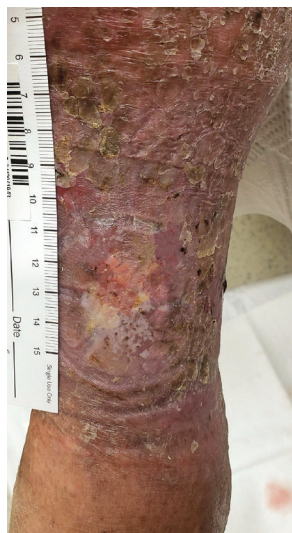

Figure 12: Case 2 wound closure was achieved by week 9 of therapy.

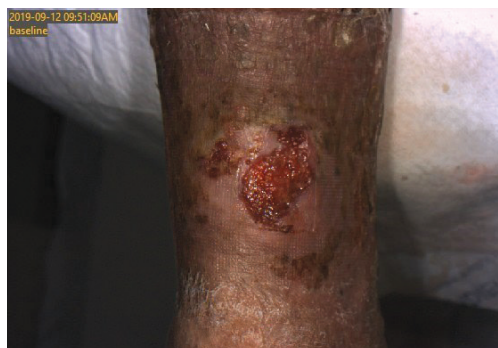

Figure 8: Case 2 initial intake wound photo.

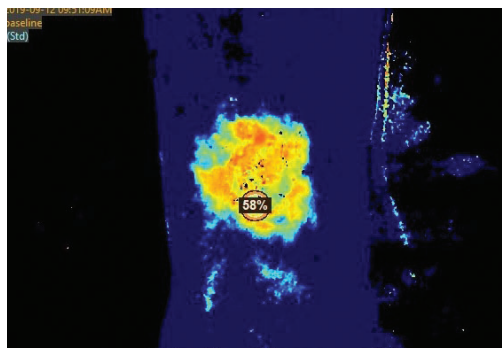


Figure 9: Case 2 baseline oxygenated hemoglobin level was 58%.

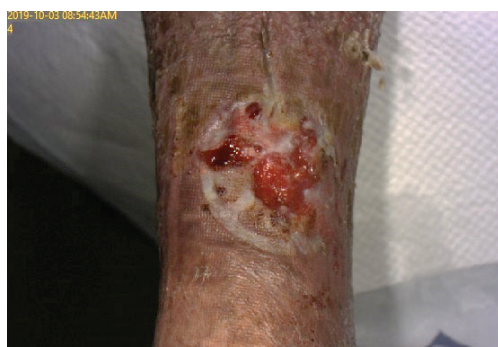

Figure 10: Case 2 at week 3 of therapy shows new islands of epithelial tissue.

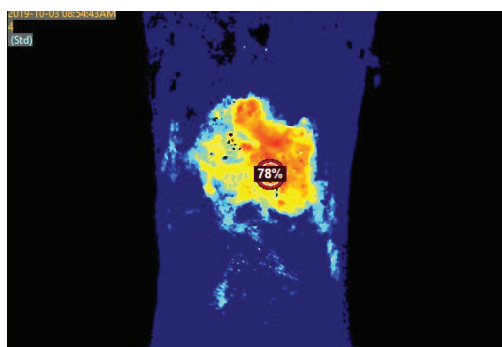


Figure 11: Case 2 oxygenated hemoglobin level increased to 78% at the 3-week mark.

WOUND MANAGEMENT

Oxygen (from page 98)

commercially available and more are entering into the market. Clinicians should keep up on the ever-changing data regarding supplemental oxygen therapy in wound care. **PM**

References

- ¹ Tandara AA, Mustoe TA. Oxygen in wound healing--more than a nutrient. *World J Surg.* 2004;28(3):294-300.
- ² Rodriguez PG, Felix FN, Woodley DT, Shim EK. The role of oxygen in wound healing: a review of the literature. *Dermatol Surg.* 2008;34(9):1159-1169.
- ³ Li, J., Chen, J., & Kirsner, R. (2007). Pathophysiology of acute wound healing. *Clinics in dermatology*, 25(1), 9-18.
- ⁴ Heyworth, P. G., Cross, A. R., & Curmutte, J. T. (2003). Chronic granulomatous disease. *Current opinion in immunology*, 15(5), 578-584.
- ⁵ Hohn DC, MacKay RD, Halliday B, Hunt TK. Effect of O₂ tension on microbicidal function of leukocytes in wounds and in vitro. *Surg Forum.* 1976;27(62):18-20. Bishop A. Role of oxygen in wound healing. *J Wound Care.* 2008;17(9):399-402.
- ⁶ Steed, D. L. (1997). The role of growth factors in wound healing. *Surgical Clinics of North America*, 77(3), 575-586.
- ⁷ Bishop A. Role of oxygen in wound healing. *J Wound Care.* 2008;17(9):399-402.
- ⁸ Siddiqui A, Galiano RD, Connors D, Gruskin E, Wu L, Mustoe TA. Differential effects of oxygen on human dermal fibroblasts: acute versus chronic hypoxia. *Wound Repair Regen.* 1996;4(2):211-218.

⁹ Rappu P, Salo AM, Myllyharju J, Heino J. Role of prolyl hydroxylation in the molecular interactions of collagens. *Essays Biochem.* 2019;63(3):325-335. Published 2019 Sep 13. doi:10.1042/EBC20180053.

¹⁰ Hunt TK, Pai MP. The effect of varying ambient oxygen tensions on wound metabolism and collagen synthesis. *Surg Gynecol Obstet.* 1972;135(4):561-567.

¹¹ Gordillo GM, Sen CK. Revisiting the essential role of oxygen in wound healing. *Am J Surg.* 2003;186(3):259-263.

¹² Mutluoglu M, Cakkalkurt A, Uzun G, Aktas S. Topical Oxygen for Chronic Wounds: a pro/con debate. *J American College of Clinical Wound Specialists* (2015) 5, 61-5

¹³ Dissemmond J, Kroger K. Topical Oxygen Wound Therapies for Chronic Wounds: a Review. *J Wound Care.* 2015;24(2):53-63.



Dr. Cole is an Adjunct Professor and Director of Wound Care Research at Kent State University College of Podiatric Medicine. She also serves as Director of Wound Care Services for Cleveland Regency East Hospital and is the Medical Director at University Hospitals Ahuja Wound Care Center. She is board certified by the American Board of Podiatric Surgery. Her practice focus is on advanced wound care modalities and regenerative medicine. She has published on these topics and speaks nationally and internationally on limb preservation and wound care.

CME EXAMINATION

SEE ANSWER SHEET ON PAGE 101.

- 1) Which is a true statement about the Krebs cycle?
 - A) It is an anerobic process.
 - B) ADP is the fuel needed for all human cellular processes to occur.
 - C) Oxygen is the final electron acceptor in the synthesis of ATP.
 - D) Hypoxia does not affect this process.
- 2) Why is oxygen important for bacteria management in wounded tissue?
 - A) Without oxygenation the respiratory burst is impaired.
 - B) Devitalized tissue may remain in the wound bed making bacterial colonization more likely.
 - C) Lack of oxygen has been shown to increase tissue susceptibility to infection.
 - D) All of the above.
- 3) All statements about growth factor regulation are true except:
 - A) Acute hypoxia decreases growth factor production, but chronic hypoxia stimulates it.
 - B) Transition between wound healing phases is managed by growth factors.
 - C) Fibroblast migration is in direct response to growth factor release.
 - D) Low levels of local oxygen are detrimental to growth factor production.
- 4) Collagen and procollagen formation differ in what way?
 - A) Unlike procollagen, collagen fibers exhibit a tight triple helical structure.
 - B) Fibroblasts secrete collagen but not procollagen.
 - C) Hydroxylation of the proline and lysine side chains is not required to form procollagen.
 - D) Both a and c.
- 5) How does the level of local oxygen influence the rate of wound healing?
 - A) Increased oxygen levels can speed the rate of collagen deposition.
 - B) Hyperoxic environments decrease collagen synthesis.
 - C) The Hunt and colleagues rabbit study showed that breathing air with increased oxygen had little effect on wound healing.
 - D) Oxygen levels do not impact the rate of wound healing.
- 6) All statements are true regarding angiogenesis except:
 - A) Initially hypoxia acts as a stimulus to angiogenesis.
 - B) Angiogenesis begins through budding of the existing capillary network.

Continued on page 100

- C) Vascular endothelial growth factor (VEG-F) is a major influence on angiogenesis.
D) Angiogenesis is not an important part of wound healing.
- 7) The Gordillo study comparing hyperbaric oxygen therapy to topical oxygen concluded all of the following except:
A) No significant changes in wound measurements were seen in the HBOT patient group, but the TO treatment group had a noticeable decrease in wound dimensions.
B) There was an increase in VEG-F found within the wounds of the TO group.
C) The TO group exhibited better overall wound healing compared to the HBOT group.
D) HBOT and TO had similar effects on wound healing.
- 8) How do systemic disease states contribute to decreased rates of wound healing?
A) Patients with co-morbidities are more non-compliant.
B) Diabetes and PVD do not complicate wound healing.
C) Chronic disease states commonly cause decreased circulation, inactivation of growth factors, and cellular senescence.
D) Co-morbid states increase patients' physical fitness.
- 9) Which statement is correct regarding HBOT?
A) The origins of HBOT can be traced back to 1860.
B) HBOT has gained acceptance within the medical community as a viable adjunct wound care therapy.
C) HBO is inexpensive and can be used in a broad cross-section of patients.
D) There are no known side-effects of HBOT.
- 10) Chronic wounds display which of the following?
A) A prolonged inflammatory phase.
B) Low mitogenic activity.
C) A dysfunctional matrix.
D) All of the above.

SEE ANSWER SHEET ON PAGE 101.

The author(s) certify that they have NO affiliations with or involvement in any organization or entity with any financial interest (such as honoraria; educational grants; participation in speakers' bureaus; membership, employment, consultancies, stock ownership, or other equity interest), or non-financial interest (such as personal or professional relationships, affiliations, knowledge, or beliefs) in the subject matter or materials discussed in this manuscript.

PM's CME Program

Welcome to the innovative Continuing Education Program brought to you by *Podiatry Management Magazine*. Our journal has been approved as a sponsor of Continuing Medical Education by the Council on Podiatric Medical Education.

Now it's even easier and more convenient to enroll in PM's CE program!

You can now enroll at any time during the year and submit eligible exams at any time during your enrollment period.

CME articles and examination questions from past issues of *Podiatry Management* can be found on the Internet at <http://www.podiatrym.com/cme>. Each lesson is approved for 1.5 hours continuing education contact hours. Please read the testing, grading and payment instructions to decide which method of participation is best for you.

Please call (631) 563-1604 if you have any questions. A personal operator will be happy to assist you.

Each of the 10 lessons will count as 1.5 credits; thus a maximum of 15 CME credits may be earned during any 12-month period. You may select any 10 in a 24-month period.

The Podiatry Management Magazine CME program is approved by the Council on Podiatric Education in all states where credits in instructional media are accepted. This article is approved for 1.5 Continuing Education Contact Hours (or 0.15 CEU's) for each examination successfully completed.

PM's privacy policy can be found at <http://podiatrym.com/privacy.cfm>.

This CME is valid for CPME-approved credits for three (3) years from the date of publication.

Enrollment/Testing Information and Answer Sheet

Note: If you are mailing your answer sheet, you must complete all info. on the front and back of this page and mail with your credit card information to: **Program Management Services, P.O. Box 490, East Islip, NY 11730.**

TESTING, GRADING AND PAYMENT INSTRUCTIONS

(1) Each participant achieving a passing grade of 70% or higher on any examination will receive an official computer form stating the number of CE credits earned. This form should be safeguarded and may be used as documentation of credits earned.

(2) Participants receiving a failing grade on any exam will be notified and permitted to take one re-examination at no extra cost.

(3) All answers should be recorded on the answer form below. For each question, decide which choice is the best answer, and circle the letter representing your choice.

(4) Complete all other information on the front and back of this page.

(5) Choose one out of the 3 options for testgrading: mail-in, fax, or phone. To select the type of service that best suits your needs, please read the following section, "Test Grading Options".

TEST GRADING OPTIONS

Mail-In Grading

To receive your CME certificate, complete all information and mail with your credit card information to: **Program Management Services, P.O. Box 490, East Islip, NY 11730. PLEASE DO NOT SEND WITH SIGNATURE REQUIRED, AS THESE WILL NOT BE ACCEPTED.**

There is **no charge** for the mail-in service if you have already enrolled in the annual exam CME program, and we receive this exam during your current enrollment period. If you are not enrolled, please send \$29.00 per exam, or \$249 to cover all 10 exams (thus saving \$41 over the cost of 10 individual exam fees).

Facsimile Grading

To receive your CME certificate, complete all information and fax 24 hours a day to 1631-532-1964. Your CME certificate will be dated and mailed within 48 hours. This service is available for \$2.95 per exam if you are currently enrolled in the annual 10-exam CME program (and this exam falls within your enrollment period), and can be charged to your Visa, MasterCard, or American Express.

If you are *not* enrolled in the annual 10-exam CME program, the fee is \$29 per exam.

Phone-In Grading

You may also complete your exam by using the toll-free service. Call 1-800-232-4422 from 10 a.m. to 5 p.m. EST, Monday through Friday. Your CME certificate will be dated the same day you call and mailed within 48 hours. There is a \$2.95 charge for this service if you are currently enrolled in the annual 10-exam CME program (and this exam falls within your enrollment period), and this fee can be charged to your Visa, Mastercard, American Express, or Discover. If you are not currently enrolled, the fee is \$29 per exam. When you call, please have ready:

1. Program number (Month and Year)
2. The answers to the test
3. Credit card information

In the event you require additional CME information, please contact PMS, Inc., at **1-631-563-1604.**

ENROLLMENT FORM & ANSWER SHEET

Please print clearly...Certificate will be issued from information below.

Name _____ Email Address _____

Please Print: FIRST MI LAST

Address _____

City _____ State _____ Zip _____

Charge to: Visa MasterCard American Express

Card # _____ Exp. Date _____ Zip for credit card _____

Note: Credit card is the only method of payment. Checks are no longer accepted.

Signature _____ Email Address _____ Daytime Phone _____

State License(s) _____ Is this a new address? Yes No

Check one: I am currently enrolled. (If faxing or phoning in your answer form please note that \$2.95 will be charged to your credit card.)

I am not enrolled. Enclosed is my credit card information. Please charge my credit card \$29.00 for each exam submitted. (plus \$2.95 for each exam if submitting by fax or phone).

I am not enrolled and I wish to enroll for 10 courses at \$249.00 (thus saving me \$41 over the cost of 10 individual exam fees). I understand there will be an additional fee of \$2.95 for any exam I wish to submit via fax or phone.

Over, please

EXAM #6/20
The Role of Oxygen in Wound Healing
(Cole)

Circle:

- | | |
|------------|-------------|
| 1. A B C D | 6. A B C D |
| 2. A B C D | 7. A B C D |
| 3. A B C D | 8. A B C D |
| 4. A B C D | 9. A B C D |
| 5. A B C D | 10. A B C D |

Medical Education Lesson Evaluation

Strongly agree [5]	Agree [4]	Neutral [3]	Disagree [2]	Strongly disagree [1]
--------------------------	--------------	----------------	-----------------	-----------------------------

- 1) This CME lesson was helpful to my practice ____
- 2) The educational objectives were accomplished ____
- 3) I will apply the knowledge I learned from this lesson ____
- 4) I will makes changes in my practice behavior based on this lesson ____
- 5) This lesson presented quality information with adequate current references ____
- 6) What overall grade would you assign this lesson?
A B C D
- 7) This activity was balanced and free of commercial bias.
Yes ____ No ____
- 8) What overall grade would you assign to the overall management of this activity?
A B C D

How long did it take you to complete this lesson?

____ hour ____ minutes

What topics would you like to see in future CME lessons?
Please list :
