



[LINK: Original article at Military Medical Corps Worldwide \[ALMANAC\]](#)

Oberreiter M., Plodr. M., Vojtěch P. – Online-Journal of Worldwide Military Medicine (06/2021)

The efficacy of hyaluronic acid in combination with an antiseptic - experience from acute military-based wound care

- **Martin Oberreiter**, MD, PHD • Center for Clinical Competence Development, Masaryk University, Brno, Czech Republic
- **Michal Plodr**, MD, PhD • Dept of Emergency Medicine and Military General Medicine, Faculty of Military Health Science University of Defence, Hradec Kralove, Czech Republic
- **Vojtěch Pavlík**, MSc • Third Faculty of Medicine, Charles University, Prague, Czech Republic

Hyaluronic acid as an essential component of wound healing

Hyaluronic acid (HA) is a natural constituent of human skin, where it forms a network with proteins that bind to HA and helps to maintain skin mechanical properties.¹⁾ In addition, HA plays a structural role by retaining water, thereby maintaining a moist environment, which is critical for successful wound healing. Even Galen, a physician treating gladiators in ancient Rome, noticed that post-combat wounds healed better in moist environments.²⁾ Current guidelines for the treatment of hard-to-heal wounds also show that the maintenance of moisture is crucial.³⁾

When skin is wounded, the structure of extracellular matrix (ECM), including HA, is compromised. Subsequently, the fragments of hyaluronan initiate angiogenesis and modulate inflammatory signaling. Hyaluronan de novo synthesis is stimulated to regenerate the structural integrity of the skin alongside other molecules such as collagen and fibronectin.⁴⁾ Hyaluronan helps to create a favorable environment for fibroblasts that form granulation tissue matrix.⁵⁾

Hyaluronan also supports reepithelization and stimulates migration of keratinocytes. When keratinocytes are prevented from binding to HA, reepithelization is significantly slower.⁶⁾ In contrast, when hyaluronan is added to wounds, reepithelization is faster.⁷⁾

Moreover, the magnitude of hyaluronan production during wound healing corresponds to more pleasing aesthetic outcomes, since the prolonged synthesis and lower inflammation produced with application of hyaluronan has been shown in scarless wound healing.⁸⁾

Given the proven benefits that hyaluronan brings to wound healing, it has been successfully used in various formulations to treat non-infected chronic and acute traumatic wounds as well as burns.⁹⁾ Since bacteria complicate wound healing, antiseptics are used in combination with hyaluronan to ensure healing as well as antimicrobial action of these wound-healing devices.¹⁰⁾ Since war injuries are considered to be contaminated, the standard treatment is a thorough debridement and delayed primary closure. Nevertheless, the shape of the wounds often presents a challenge for a surgeon since gunshot or shrapnel wounds create cavities that are difficult to debride.

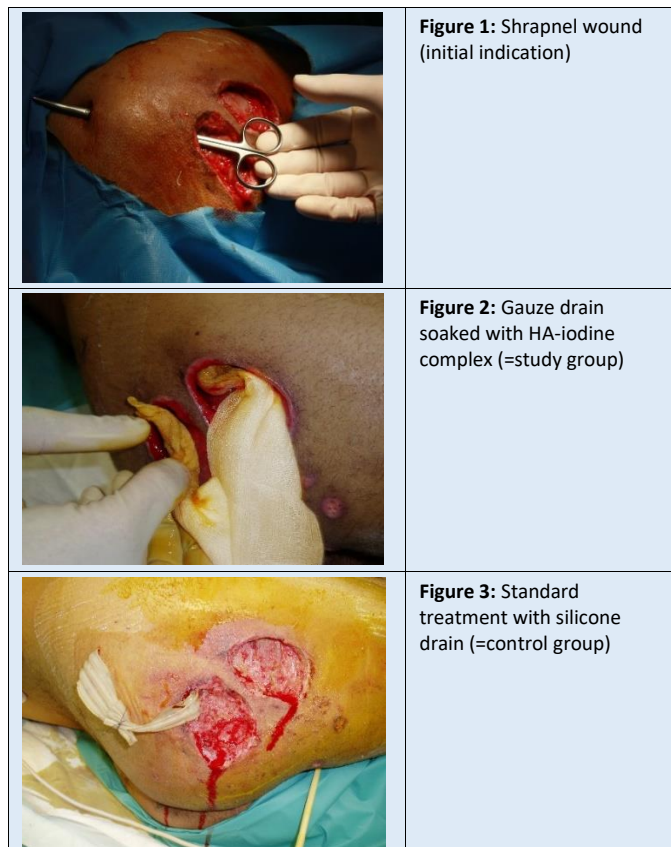
Therefore, we evaluated debriding properties and pro-healing action of a fluid containing HA and iodine. Our hypothesis was that after the initial debridement, HA would stimulate healing and iodine would prevent bacterial growth. To the best of our knowledge, this study is the first to present use of a formulation of viscous HA and iodine applied to acute war wounds before primary delayed suture. For this purpose, we used a medical device (hyaluronan-iodine fluid) from the company Contipro. According to our first results, the

treatment evinced an excellent effect in the management of these wounds.

Treatment group

The observational, comparative study was conducted by a surgical team at the field hospital of the army of the Czech Republic in Afghanistan. The study group and the control group included exclusively gunshot wounds and shrapnel injuries (Figure 1) of 14 soldiers (age: 15-35 years) with 19 wounds (abbreviated Injury Scale < 9). All wounds were regarded as heavily colonized or infected.

The treatment in the study group with a HA-iodine complex was performed in 5 patients (7 wounds in total) for comparison with a matching control group (9 patients with a total of 12 wound). Both groups underwent standard surgical debridement, pulsatile lavage and drainage of the wound. The drainage used for the study group was a gauze soaked with a hyaluronan-iodine complex (Figure 2), whereas silicone drains were applied in the control group (Figure 3). The treatment was evaluated on a regular basis until clean granulation tissue formed, which allowed for the patients to be transported to a hospital in Afghanistan.

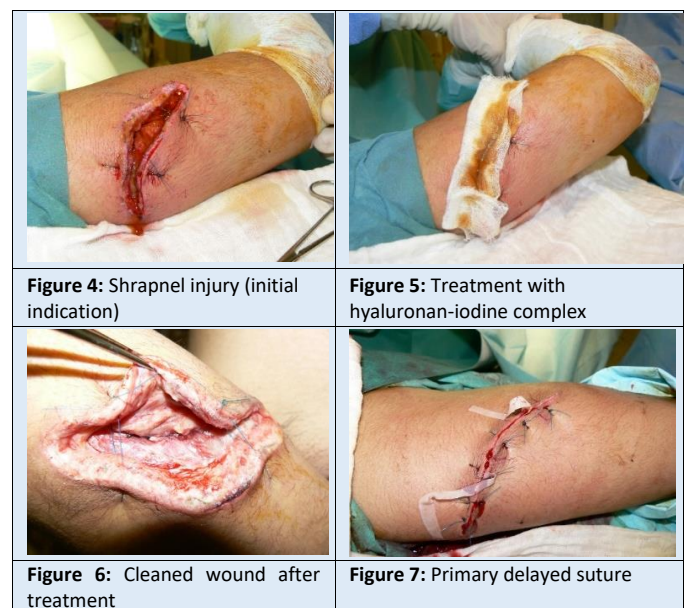


Results of hyaluronan with iodine application

Below we present two case reports to better demonstrate the method of treatment and the results.

Case 1 – A shrapnel injury

A young soldier incurred shrapnel injury of the right arm. In the first line local medical facility a primary suture was performed. After 24 hours the patient was transported to the field hospital. Entry examination revealed signs of infection like *Staphylococcus-aureus* according to the microbial examination. Under general anesthesia the stitches were removed, and the wound was debrided and rinsed. Afterwards the wound was filled with a gauze soaked with HA-iodine complex and left open. During the next 4 days the wound was redressed every 24 hours in the same manner. After 4 days the swab was negative and the wound showed no signs of infection. As a result, primary delayed suture was done. The wound healed after 8 days without any complications.

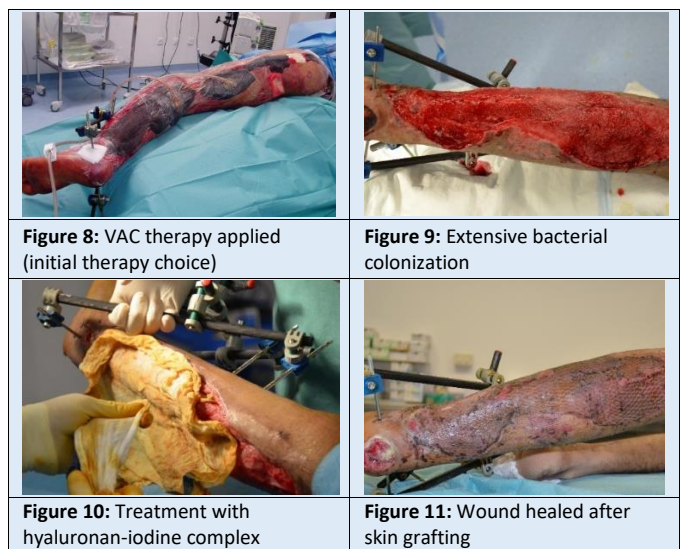

Case 2 - Complex wound resulting from an explosive device

An 18-year-old soldier, survivor of an improvised explosive device (IED), incurred complex trauma of the left leg. After primary surgical treatment, a negative pressure therapy was indicated. However, ten days after negative pressure was started, extensive bacterial

colonization of the wound was apparent under the foam. Therefore, the treatment strategy was changed.

The wound was dressed daily with a HA-iodine complex soaked gauze. After 4 days of this treatment, the wound was clean and granulated. Dermo-epidermal meshed skin grafts were applied and showed 95% successfully healing. The patient's soft tissues healed completely and he was able to walk with crutches just 6 weeks after the injury.



Summary

Treatment with a hyaluronan-iodine complex in the study group significantly reduced the time necessary to clean both gunshot and shrapnel wounds (Table 1). Moreover, the development of clean and vital granulation tissue was observed soon after the initial treatment. Treating physicians and nurses were very satisfied with the antimicrobial effect that this medical device produced. In addition, they appreciated the cleaning of gun-shot wounds from particles (gunpowder, soil) with the HA-iodine complex gauze. Fine particles were absorbed into the soaked gauze, greatly facilitating the debridement of the wound.

Synergistic effects of this method (antimicrobial, mechanical cleaning, regenerative) enabled us to conduct the primary sutures within 4 days after the injury, in comparison to the control group with standard treatment of 8 days. According to these results, treatment of combat wounds with a hyaluronan-iodine complex demonstrates significantly superior results

compared to the standard treatment. The initially reddish-brown inherent color of the hyaluronan-iodine fluid disappears 40 minutes after application and does not lead to any discoloration of the healing wound bed. Furthermore, no unexpected side effects or drug interactions were observed in any patient in the study group.

Type of injury	Time until clean granulation tissue - without any signs of infection [days]		Difference in healing speed against control group	
	Study group Hyaluronan iodine complex [n=5]	Control group Silicone drain [n=9]	Shortening [days]	Improvement [%]
	\bar{x}	\bar{x}	\bar{x}	%
Gunshot wounds	1	2.5	1.5	60
Shrapnel wounds	1.5	2	0.5	25
Total	1	2	1	50
1st quartile	1	1	p<0.05	
3rd quartile	1.5	3		

Table 1: Time to achieve clean tissue and healing speed in days (median)

Discussion

The use of antimicrobial HA products in mission-related wound care is a convincing therapeutic approach with an excellent clinical outcome. Similarly to the war wounds, several medical devices based on HA were successfully used to treat chronic ulcers, burns, and surgical abdominal wounds.¹¹⁾

Similar to the viscous HA fluid, an active layer comprising synergistic combination of active ingredients of HA lyophilizate and an antiseptic octenidine on a wound dressing evinced better slough removal and better healing dynamics than a standard dressing with silver.¹²⁾

Hyaluronic acid is an outstanding substance among local therapeutics that is used in a wide variety of specialties to promote wound healing.¹³⁾ The body of literature highlighting the importance of hyaluronan in wound care includes more than 80 publications of basic research, over 20 reviews, and more than 30 controlled comparative and case studies. When combined with antiseptics, hyaluronan can be applied across all wound phases and helps to overcome therapy resistance, stagnation or wound chronification, in addition to accelerating wound healing.

Conclusion

We observed favorable wound healing progress in this small comparative study. All wounds treated with hyaluronan-iodine fluid showed significantly faster wound healing dynamics than the standard wound care procedure. The HA-iodine formulation also restored wound healing in the wounds that stalled. Especially in the medical treatment of complex and contaminated combat injuries, the combination of HA and antibacterial iodine is an effective and safe therapeutic option.

References:

- 1) **Abatangelo G. et al (2020):** Hyaluronic Acid: Redefining Its Role. *Cells*. 2020 Jul 21;9(7):1743 [ABSTRACT](#)
- 2) **Mattern S.P. (2013):** The Prince of Medicine: Galen in the Roman Empire. Oxford University Press, 2013 [BOOK](#)
- 3) **Boersema C.G. et al. (2021):** Management of Nonhealable and Maintenance Wounds: A Systematic Integrative Review and Referral Pathway. *Adv Skin Wound Care*. 2021 Jan;34(1):11-22 [ABSTRACT](#)
- 4) **Dovedytis M. et al. (2020):** Hyaluronic acid and its biomedical applications: A review. *Engineered Regeneration* 1 (2020) 102–113 [ABSTRACT](#)
Pavlik V. et al. (2021): Silver distribution in chronic wounds and the healing dynamics of chronic wounds treated with dressings containing silver and octenidine. *The FASEB Journal*. 2021;00:e21580 [ABSTRACT](#)
- 5) **Schneider H.P., Landsman A. (2019):** Preclinical and Clinical Studies of Hyaluronic Acid in Wound Care: A Case Series and Literature Review. *Wounds*. 2019 Feb;31(2):41-48 [ABSTRACT](#)
- 6) **Shatirishvili M. et al. (2016):** Epidermal-specific deletion of CD44 reveals a function in keratinocytes in response to mechanical stress. *Cell Death Dis*. 2016 Nov 10;7(11):e2461 [ABSTRACT](#)
- 7) **Catanzano O. (2015):** Alginate-hyaluronan composite hydrogels accelerate wound healing process. *Carbohydr Polym*. 2015 Oct 20;131:407-14 [ABSTRACT](#)
- 8) **Kawano Y. et al. (2021):** Wound Healing Promotion by Hyaluronic Acid: Effect of Molecular Weight on Gene Expression and In Vivo Wound Closure. *Pharmaceuticals (Basel)*. 2021 Mar 28;14(4):301 [ABSTRACT](#)

Monavarian M. et al. (2019): Regenerative Scar-Free Skin Wound Healing. *Tissue Eng Part B Rev*. 2019 Aug;25(4):294-311 [ABSTRACT](#)

- 9) **Voigt J., Driver V.R. (2012):** Hyaluronic acid derivatives and their healing effect on burns, epithelial surgical wounds, and chronic wounds: a systematic review and meta-analysis of randomized controlled trials. *Wound Repair Regen*. 2012 May-Jun;20(3):317-31 [ABSTRACT](#)

King I. C. C., Sorooshian P. (2020): Hyaluronan in skin wound healing: therapeutic applications *JWC Vol. 29, No 12, Dec 2020:782-787* [ABSTRACT](#)

- 10) **Baretto R. et al. (2020):** Addressing the challenges in antiseptics: focus on povidone iodine. *Int J Antimicrob Agents*. 2020 Sep;56(3):106064 [ABSTRACT](#)

Brennes R. A. et al. (2011): Initial experience using a hyaluronate-iodine complex for wound healing. *Am Surg*. 2011 Mar;77(3):355-9 [ABSTRACT](#)

Koyanag H. et al. (2021): Local wound management factors related to biofilm reduction in the pressure ulcer: A prospective observational study. *Jpn J Nurs Sci*. 2021 Apr;18(2):e12394 [ABSTRACT](#)

- 11) **Graçaa M.F.P. (2020):** Hyaluronic acid-Based wound dressings: A review. *Carbohydr Polym*. 2020 Aug 1;241:116364 [ABSTRACT](#)

- 12) **Stryja J. et al. (2021):** Octenidine with hyaluronan a unique combination dressing as a new alternative choice for the treatment of infected non-healing wounds to a silver-based product (draft of RCT submitted to the journal)

- 13) **Mikosinski J. et al. (2021):** Efficacy and Safety of a Hyaluronic Acid-Containing Gauze Pad in the Treatment of Chronic Venous or Mixed-Origin Leg Ulcers: A Prospective, Multicenter, Randomized Controlled Trial. *Wounds Epub* 2021 April 7 [ABSTRACT](#)

Citation:

Oberreiter M. et al. (2021): The efficacy of hyaluronic acid in combination with an antiseptic - experience from acute military-based wound care. *Worldwide Military Medicine ALMANAC* 06/2021